

Name of the patient

Date:

Age: 15 YRS

Sex: MALE

RADIOGRAPH DONE: CBCT

REF BY:

Axial, cross sectional, coronal and sagittal images were generated from CBCT machine and reconstructed using 3Diagnosys with a slice thickness of 0.15 mm

RADIOGRAPHIC FINDINGS:

TOOTH NO 23

- Mesio distally oriented impacted tooth no 23 measuring approximately 23 mm in length having single root with closed apex.
- Over retained tooth no 63
- Palatally oriented tooth no 22
- Crown of tooth no 23 is present between teeth no 22 and 24
- Crown is seen on the labial side, approximating with the labial root surface of tooth no 22
- Root apex is present close to the floor of the left nasal cavity

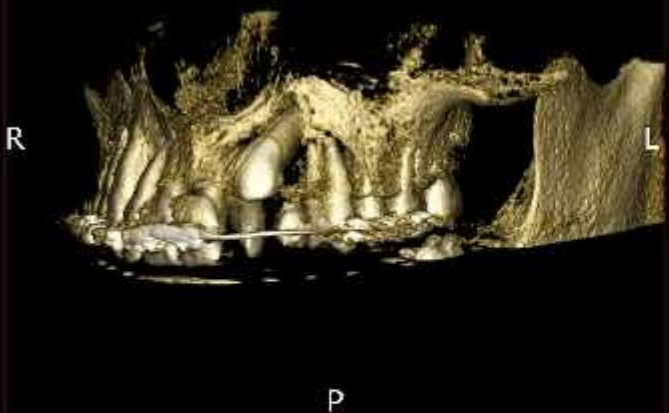
RADIOGRAPHIC DIAGNOSIS

IMPACTED 23

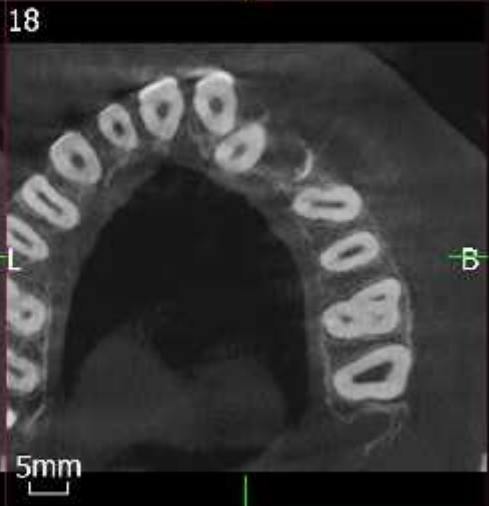
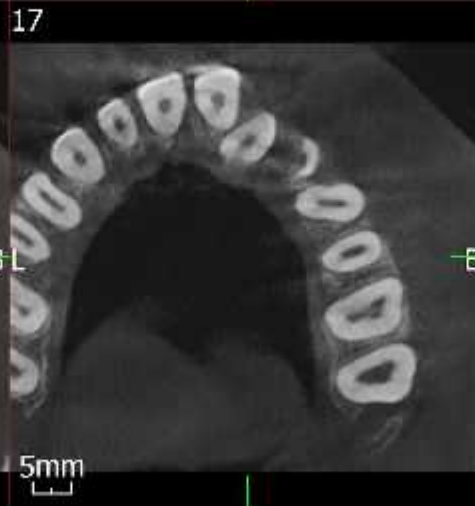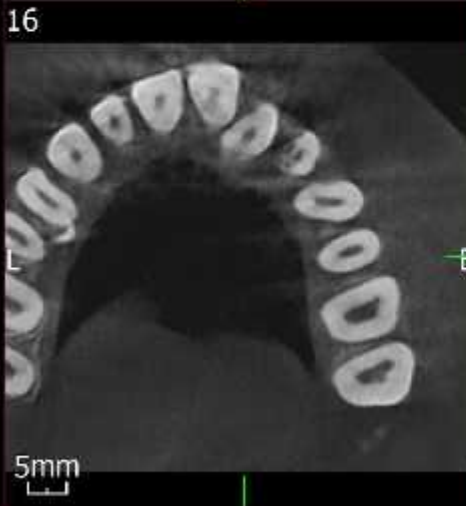
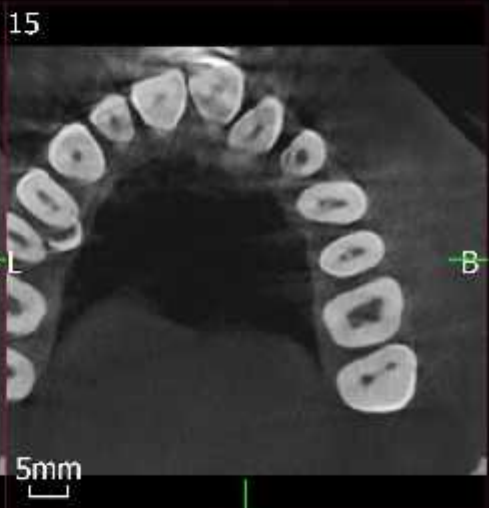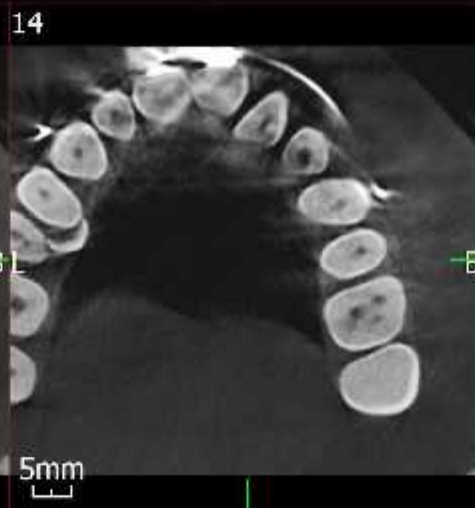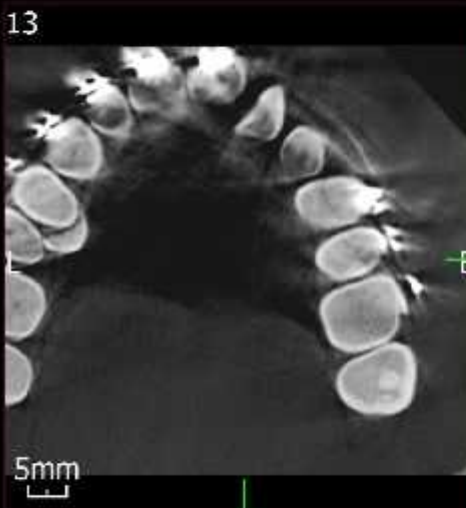
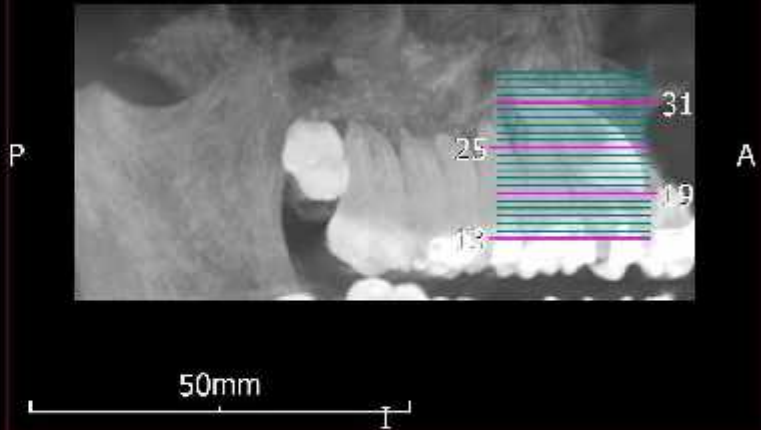
KINDLY NOTE: Co-relate clinical diagnosis with radiographic findings.

Dr Prashant P. Jaju
BDS, MDS,
Oral Maxillofacial Radiologist
Professor & Guide
Editor in Chief: CBCT magazine
Certified CBCT Trainer

A Zoom: 100%
W/L = 4000/1000

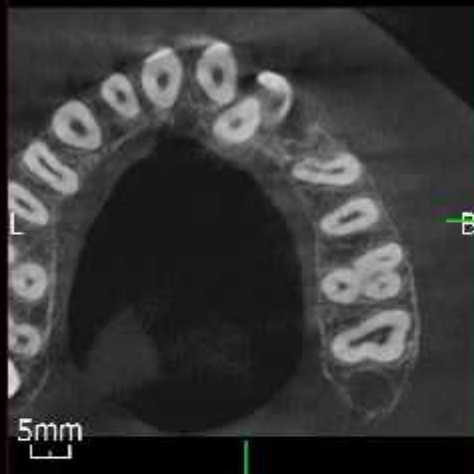


S Zoom: 100%
W/L = 4000/1000

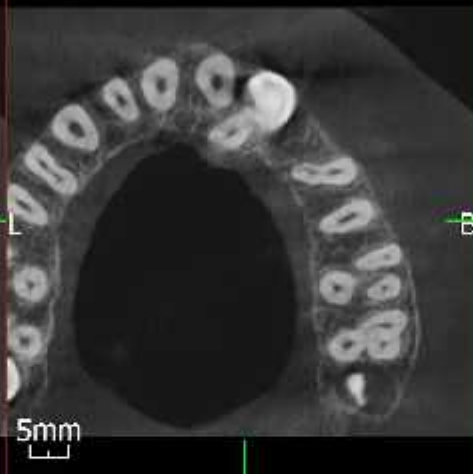


axial images of maxilla

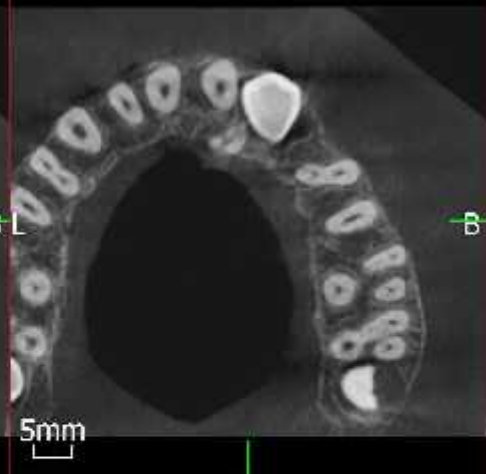19



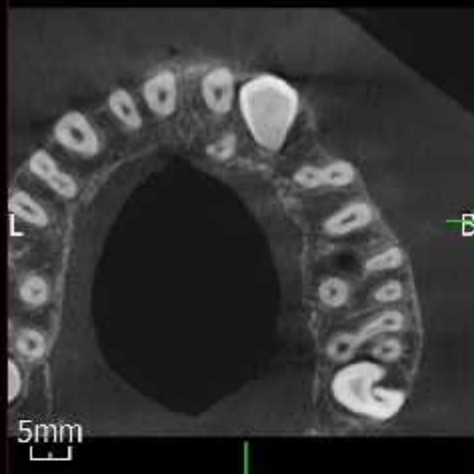
20



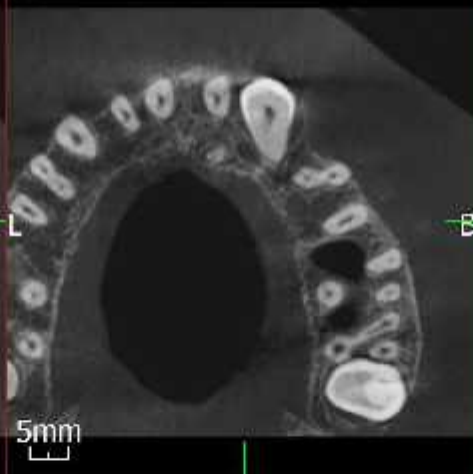
21



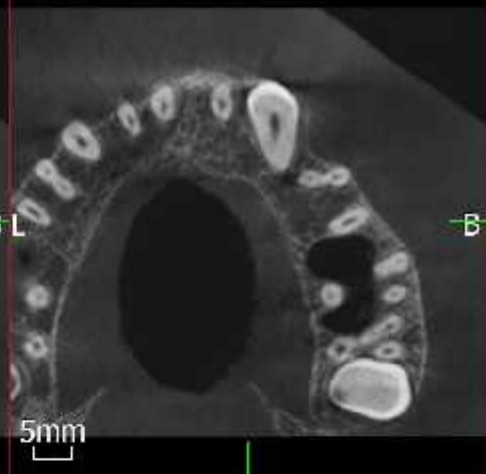22



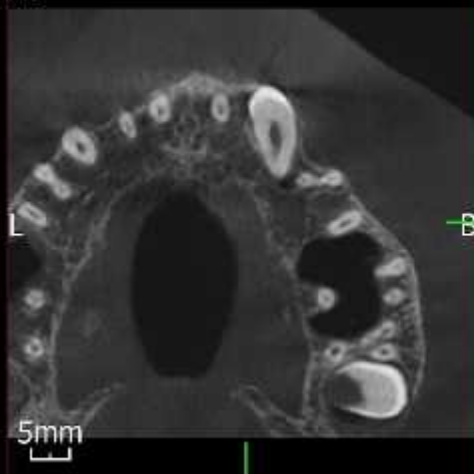23



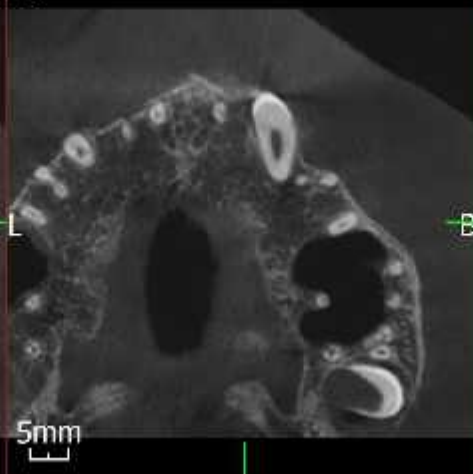
24



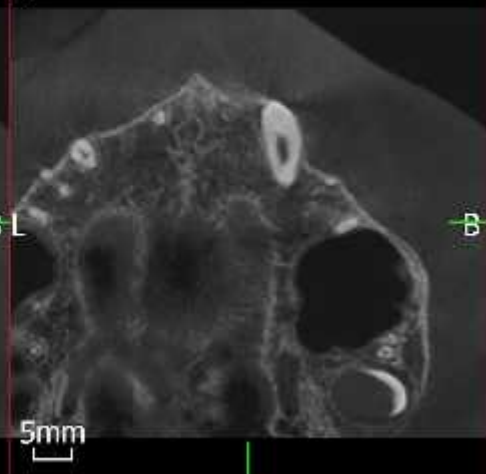
25



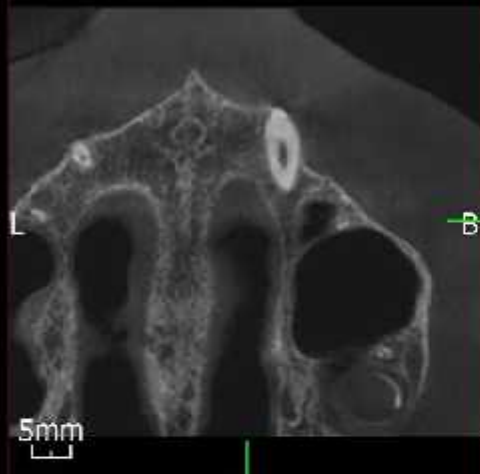26



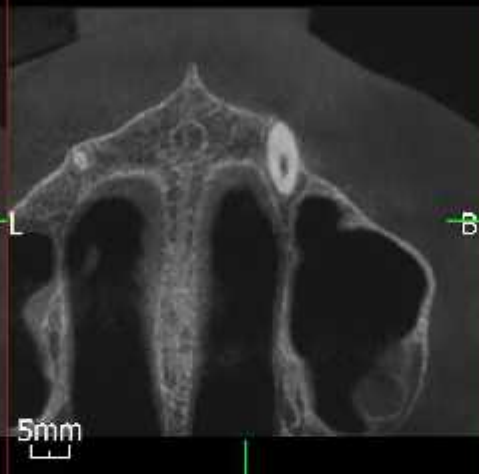27



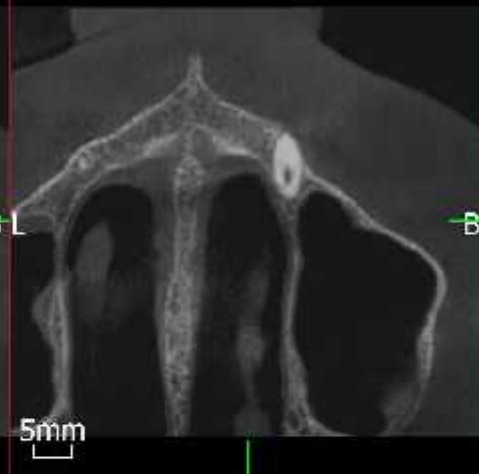28



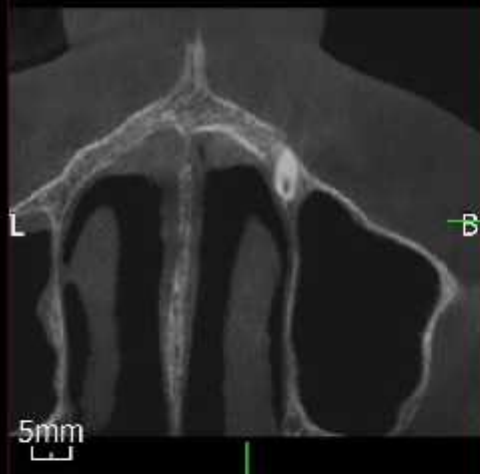29



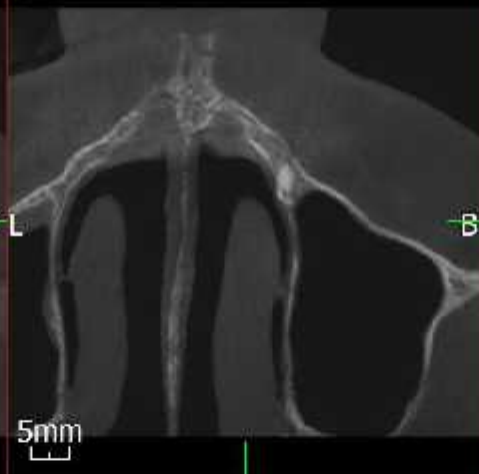30



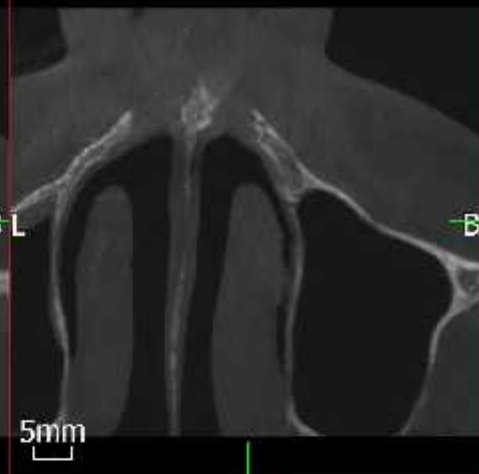31



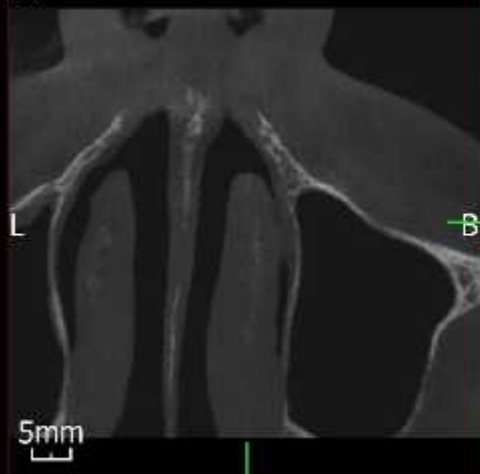32



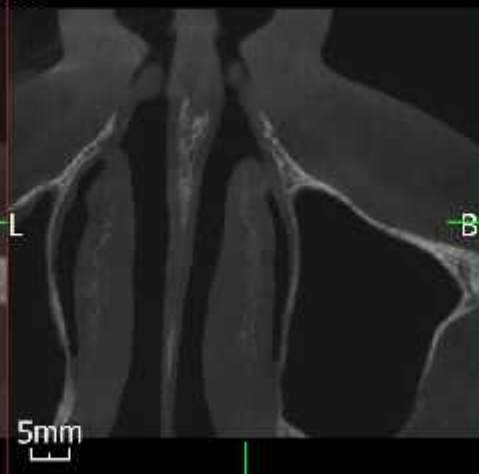33

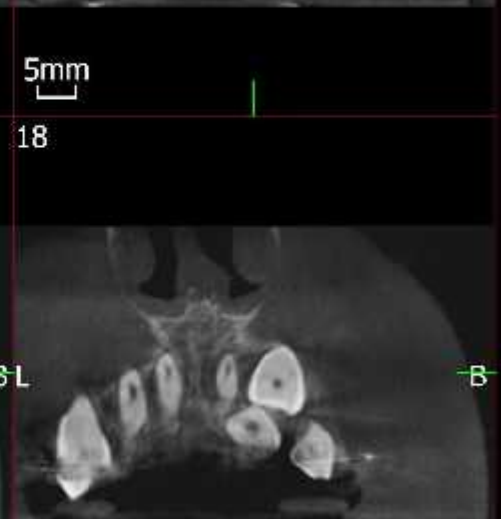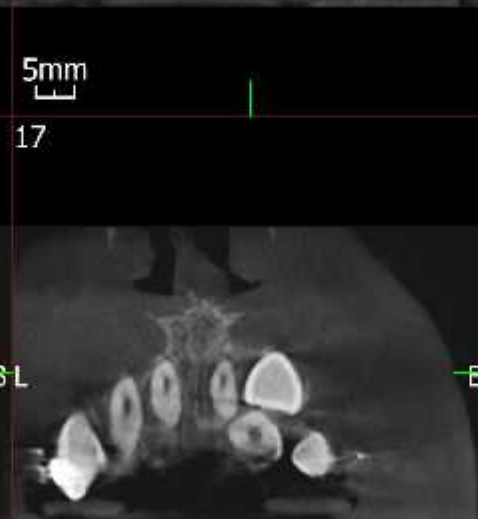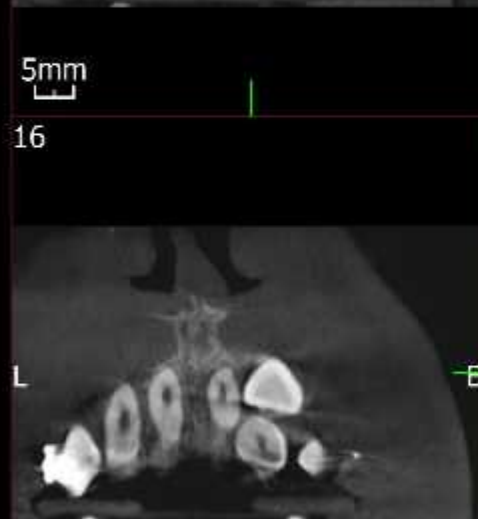
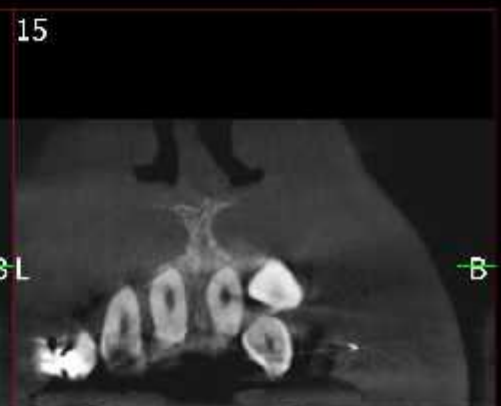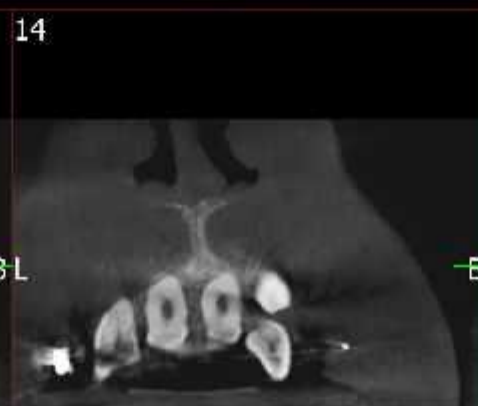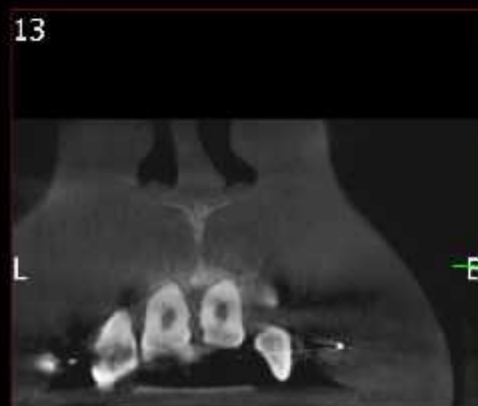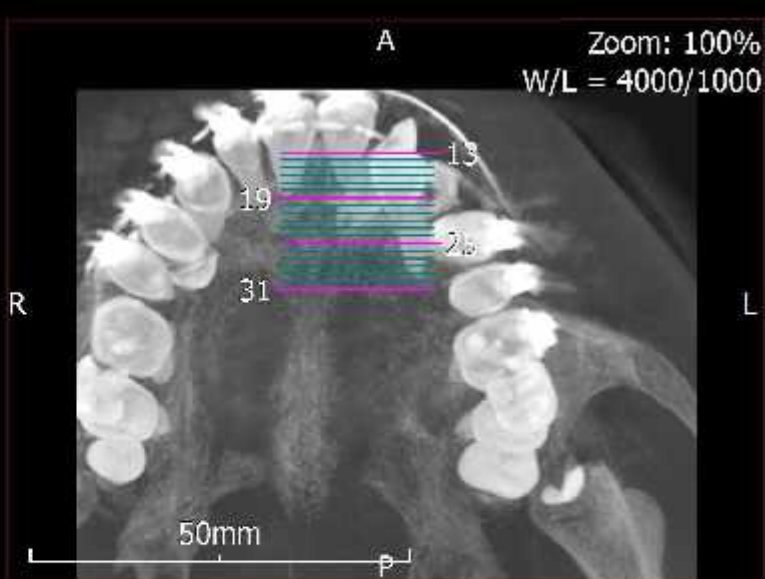
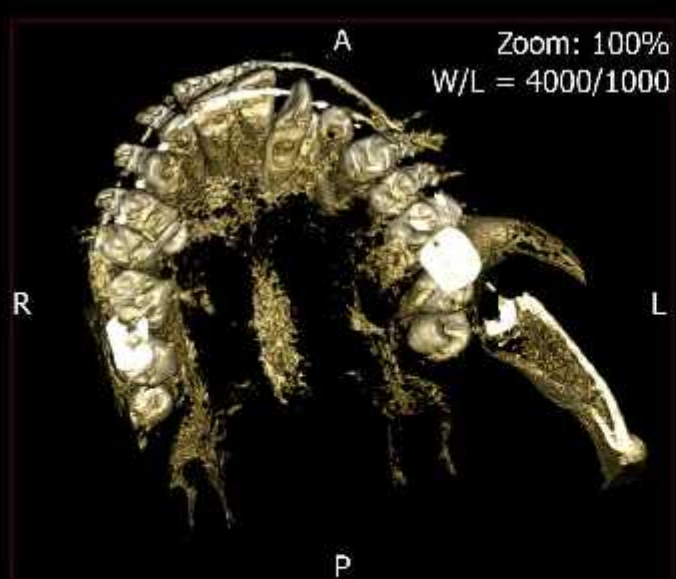


34

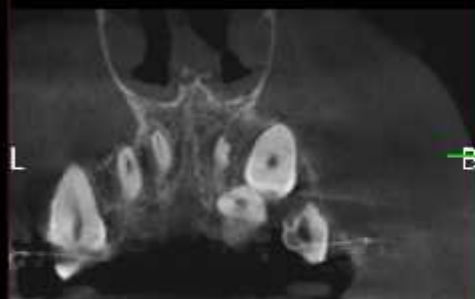

35



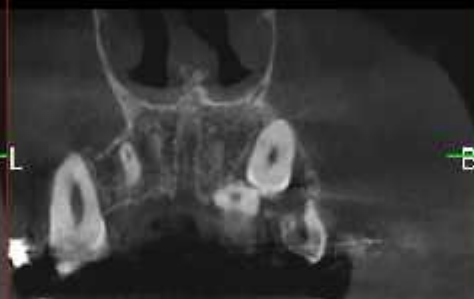

19



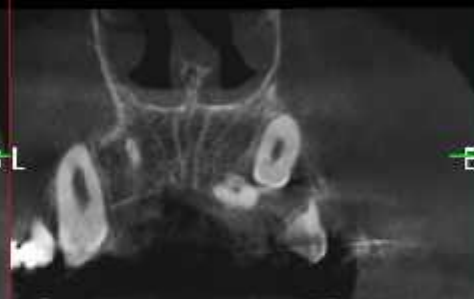5mm

20



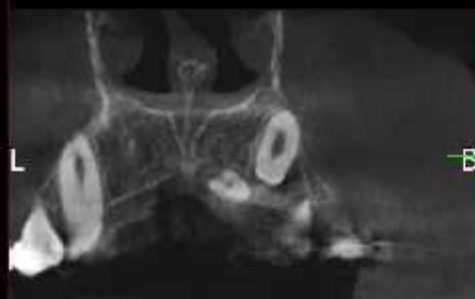5mm

21



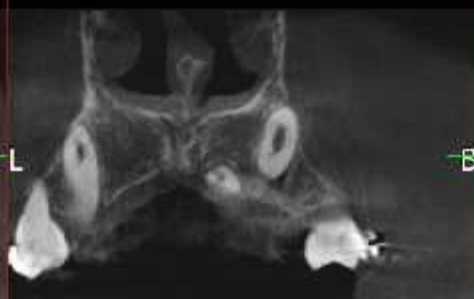5mm

22



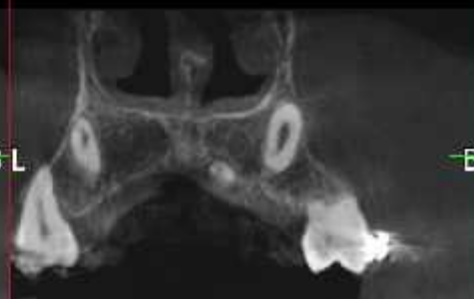5mm

23



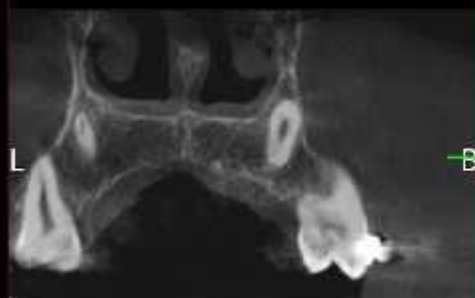5mm

24



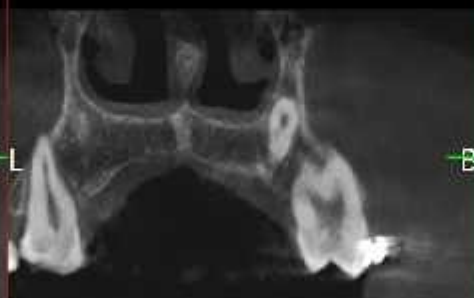5mm

25



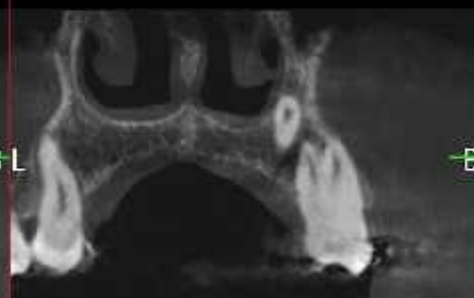
5mm

26



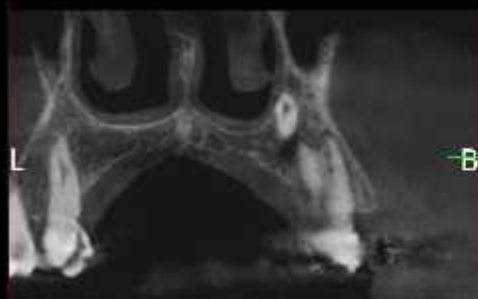
5mm

27

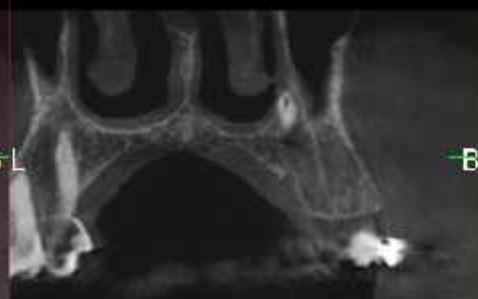

5mm

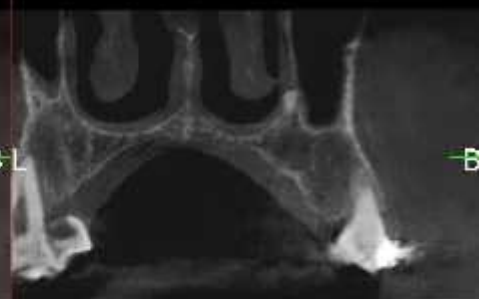
28



29



30

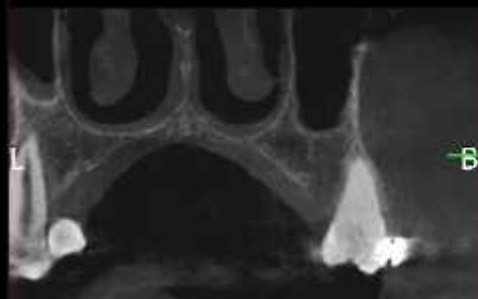


5mm

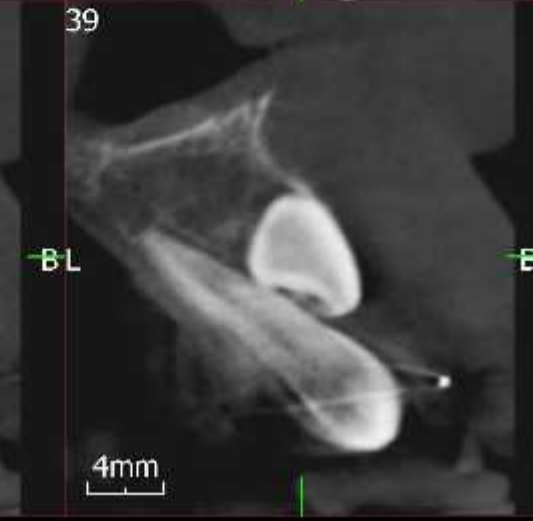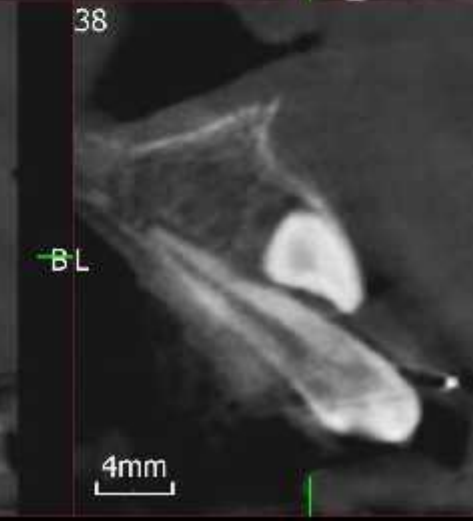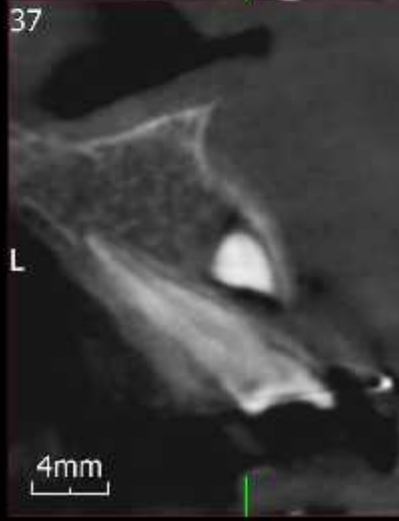
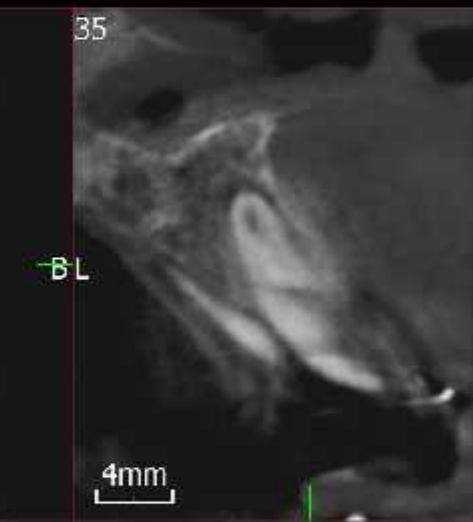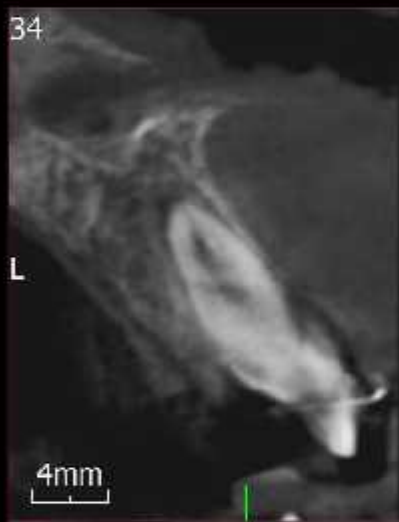
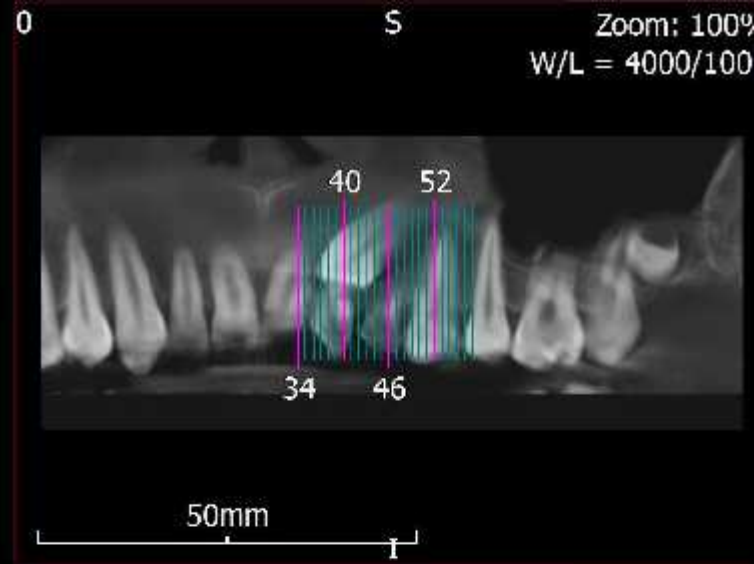
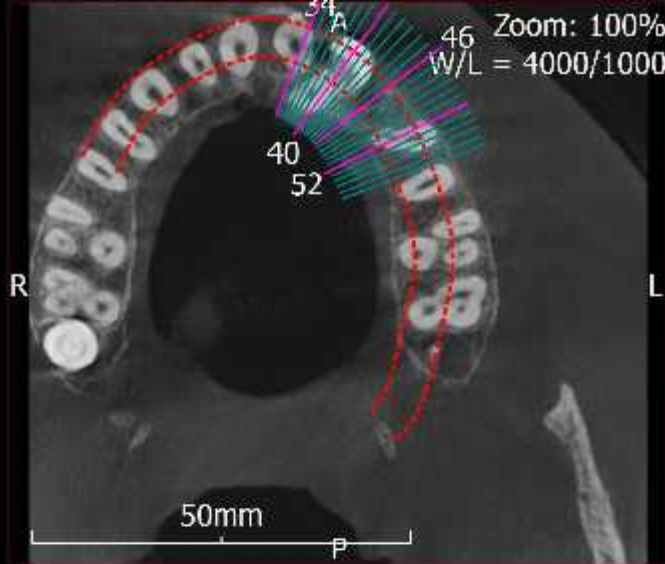
5mm

5mm

31



5mm



cpr images of maxilla

